

“Approved”

FSI “Moscow Research Institute of Oncology n.a. P. A. Herzen ROSMEDTECHNOLOGY”

Director, Member of the Russian Academy of Medical Sciences,

Professor V.I. Chissov

August 25, 2010

FSI “Moscow Research Institute of Oncology named after P.A. Herzen ROSMEDTECHNOLOGY”

**REPORT ON CLINICAL TRIALS
OF ELECTRICAL IMPEDANCE COMPUTER MAMMOGRAPH (MEIK)
WITH SOFTWARE VERSION 5.6.**

Investigators:

Diagnostic Department

Head of Diagnostic Department,

PhD, Professor Sedykh S.A.

Department of General Oncology

Head of Department of General Oncology,

PhD, Professor Pak D.D.

**REPORT ON CLINICAL TRIALS
OF ELECTRICAL IMPEDANCE COMPUTER MAMMOGRAPH (MEIK)
WITH SOFTWARE VERSION 5.6.**

Relevance

Breast cancer is one of the most important problems of modern oncology. Incidence of breast cancer (BC) among women steadily increases each year and is holding leading positions. Every year more than 1 million new cases of BC are registered worldwide. Since 1985, the given localization of cancer heads the list of cancer morbidity in Russia. In 1997, the absolute number of first ever diagnosis of BC in Russia amounted to 40 360 cases, and in 2009 it increased and reached 52 157 cases. The prevalence rate and the increase of BC mortality actualize the task of early diagnosis and improvement of Breast Diagnostic Service. For a long time the emphasis has been placed on the treatment of the disease. In Russia 94% of funds were devoted to medical treatment and only 6% to prevention. In Europe - 50% and 30% respectively. Currently, the priorities have changed: organization of screening and early detection (which enables organ-preserving treatment, enhancing quality of life and life duration) has become a higher-priority objective.

Along with the extensive use of X-ray mammography, ultrasound techniques (including improved ones on the basis of sonoelastography), considerable assistance in diagnosis is provided by Doppler sonography, duplex ultrasonography scanning, tomography (computer, magnetic resonance or positron emission), mammoscintillography. However, along with widely used radiological methods rapid technological progress has promoted the invention of radiation-free techniques for BC diagnostics. Despite the large number of modern diagnostic techniques, most women seek qualified medical care when disease has already reached III or IV stage of development. The reasons for this are the following: lack of knowledge on the early manifestations of the disease, the reluctance of women to seek routine screening or screening mammography for the age groups after 40 years and the lack of highly sensitive devices that are able to record the initial deviations from the norm.

There are no diagnostic tools providing one hundred per cent accuracy - the number of diagnostic errors when using ultrasonic and radiographic methods varies between 16% and 33%. Moreover these methods are radiological, so their usage among adolescents and young women aged from 20 to 40, pregnant and lactating women is limited in terms of frequency and applicability. The most widely used diagnostic techniques provide information on the anatomical and morphological organ condition but do not reflect its functional activity. In this regard, the usage of a radiation-free informative method for assessing the state of breast tissues seems to be reasonable: it can be suitable for wide usage in order to examine women of all ages, including pregnant women, nursing mothers as well as for screening purposes or follow-up and monitoring of the condition of mammary glands during hormone treatment. In this context the method of electrical impedance computer mammography is of great interest as it seems to be helpful when achieving these objectives.

Method

Electrical impedance mammography is one of the directions in the development of electrical impedance tomography. The electric impedance mammograph enables to image the distribution of the conductivity within biological tissues in several cross-sections of the gland and detect tumours visualizing them as areas with abnormal values of electric conductivity.



Fig.1. Electrical impedance computer mammograph MEIK

The main feature of electrical computer mammography as opposed to X-ray mammography, NMRI imaging and ultrasound techniques is that weak alternating electric current (50 kHz, 0.5 mA) is used for probing, while the sensors register the distribution of electrical potential caused by the passage of current through the medium under study. Moreover, in the electrical impedance method the source of energy and the registering sensors are positioned in one plane. X-ray tomography suggests the emitter and the receiver to be placed in different planes; they are connected with each other by straight equipotential lines, crossing the visualized volume. In case of electrical impedance mammography the equipotential lines, along which the back data projection is performed, are curved, thus it is possible to perform the topographical visualization while positioning the electrodes on the surface of the body – so that there is no need to cover it around.

The fundamental distinction from the other methods is that electrical impedance mammography enables to give metabolic assessment of the condition of the breast, calculating mean electrical conductivity and plotting graphs of electrical conductivity distribution in the breast, whereas ultrasound and X-ray techniques provide information only on anatomical characteristics of tissues under investigation.

Electrical impedance mammograph MEIK provides data for voltage on the surface of the mammary gland and the spatial distribution of specific resistivity (or conductivity) in it, thereby it informs the investigator on physiological and pathological processes occurring in the mammary gland such as: cancer, fibrocystic disease, involution, lactation etc. The measuring system and the image reconstruction algorithm employed in mammograph MEIK allow visualizing static electrical conductivity distribution in the breast tissue adjacent to the surface of electrodes. The measurements are carried out with the help of an array consisting of 256 electrodes. Electric current when passing through the tissues of the mammary gland evokes 3-D distribution of electric potential. Data transfer and measurement occur simultaneously so that a complete measurement cycle takes about 35 seconds. A method of weighted back projection along equipotential surfaces of the electric field is used to reconstruct the 3-D distribution of electrical conductivity alongside the electrodes array. This method is a generalization of the back projection method, which is used in 2-D electrical impedance tomography. The back-projection algorithm is used for the reconstruction of seven tomographic planes of the breast tissue. The procedure of reconstruction lasts about 20 seconds.

Upon the scanning procedure seven images of the mammary gland corresponding to seven scan planes (cross-sections) appear in the images field.

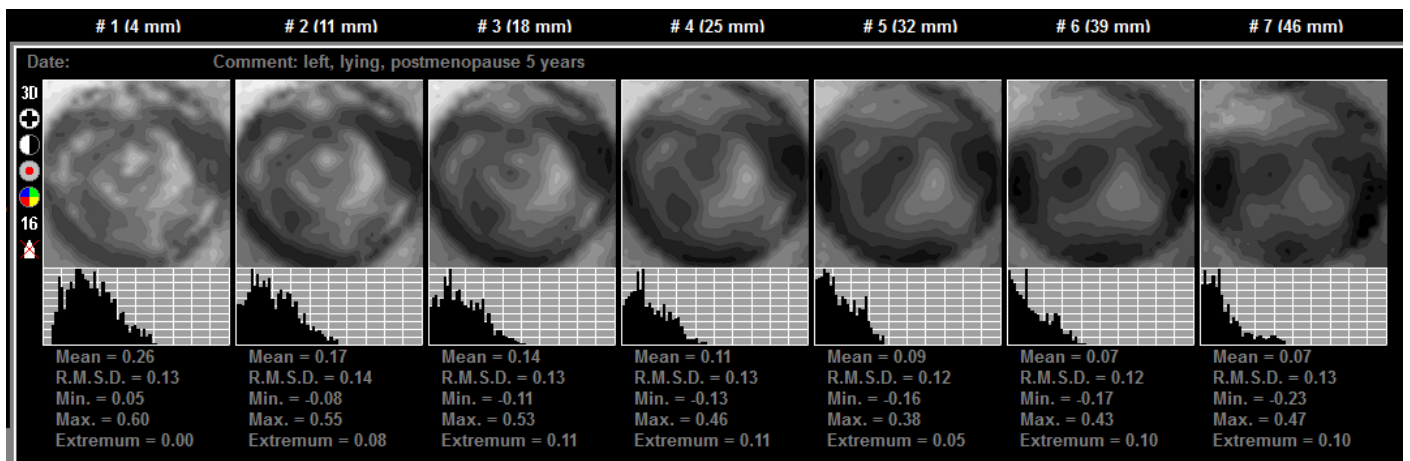


Fig.2. Seven images representing scan planes of the mammary gland.

The electrical impedance mammogram above represents the scan planes of the right mammary gland. The lesion is located in the inner quadrants of the breast.

Analysis of the obtained data includes the calculation of the mean electrical conductivity index, maximum and minimum conductivity, standard deviation and mode. Graphs of electrical conductivity distribution are plotted simultaneously. It is possible to compare electrical conductivity of the left and of the right mammary gland to the calculated percentage of electrical conductivity distribution variance.

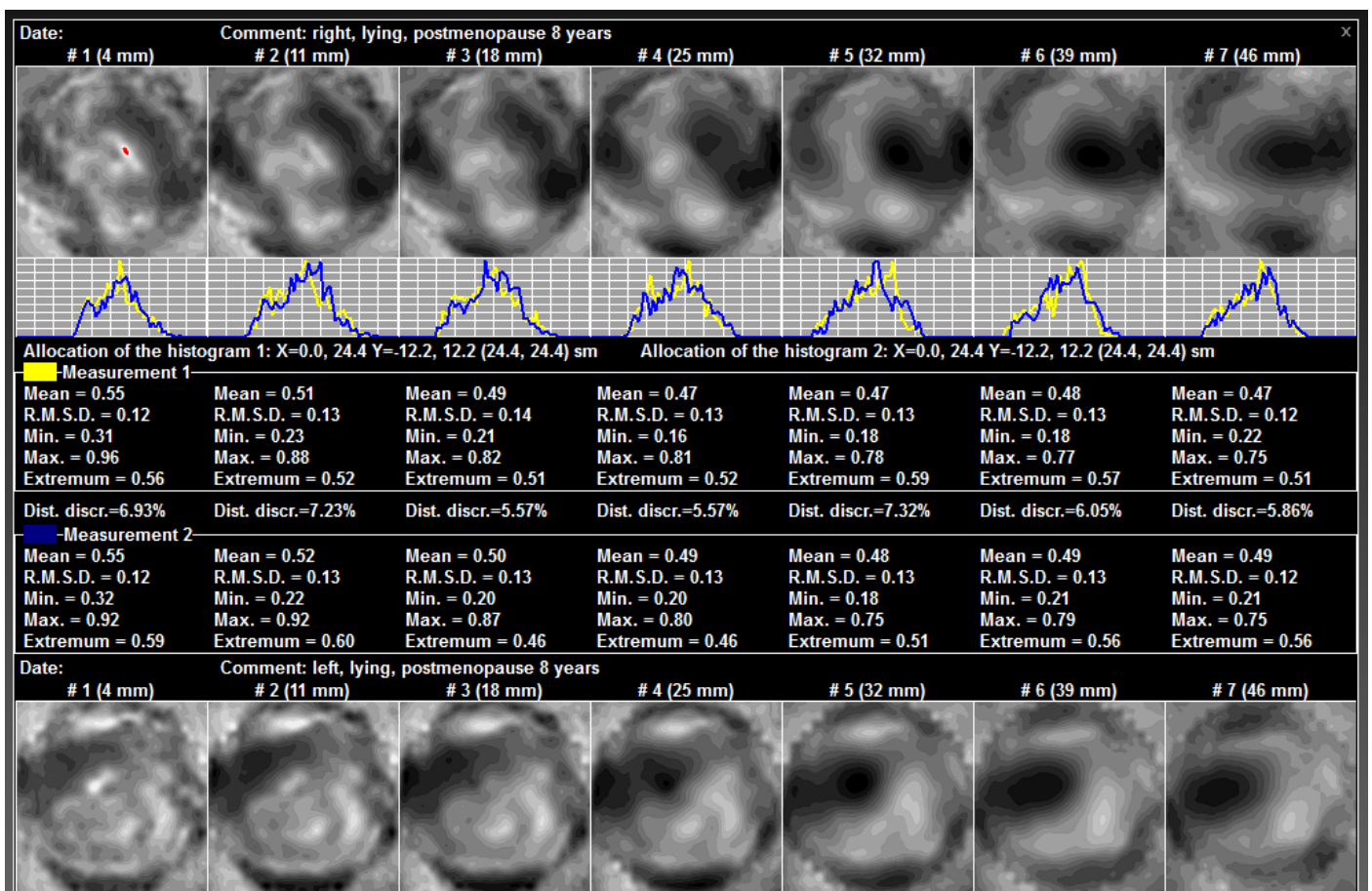


Fig.3. Comparison of electrical conductivity distribution in different mammary glands.

The comparative picture represents an electrical impedance image of right breast with a malignant tumour (after neoadjuvant polychemotherapy). Quantity and ratio of basic tissue elements (ductal and alveolar epithelial cells, collagen and elastic fibres, adipocytes, the cells of ground substance of connective tissue) determine physical and chemical properties of the mammary gland, therefore the electrical impedance tomography of the breast can be used for diagnosis of mastopathy and monitoring of its treatment.

Early detection of BC using electrical impedance mammography is made possible with change of electrical properties of breast tissue in the area of tumour and surrounding tissues. Very important for diagnosis is to distinguish specific types of cancer: nodular and oedematous-infiltrative. The former type of BC is characterized by high electrical conductivity of tumour cells and the latter - by high local or general impedance.

Testing purpose:

the test is aimed at determination of the effectiveness of the method of electrical impedance computer mammography compared to ultrasound (US) and digital X-ray mammography, definition of accuracy of the method for BC screening.

Tasks and Objectives:

- 1) determination of the probability of pathological changes in mammary glands of patients with various breast diseases and healthy women;
- 2) comparison of the percentage of pathological changes probability in the mammary gland obtained with the help of MEIK and the data acquired by means of traditional comprehensive breast screening;
- 3) assessment of the quantity of false positive and false negative results;
- 4) analysis of the medical conclusions based on the data of the three methods in use;
- 5) development of the follow-up tactics for patients after comparing the results of examination;
- 6) evaluation of MEIK as a tool for medical treatment effectiveness monitoring of the patients with diseases of mammary glands.

Materials and Methods:

The subjects of the clinical test were 117 women (from inpatient or outpatient department FSI (Federal State Institution) "MRIO n.a. P.A. Herzen"), as well as healthy women, voluntarily applied to breast screening. The age of women ranged from 22 to 84 years. The comparison of the screening results and clinical-morphological diagnosis was carried out upon the completion of electrical impedance mammography examination, calculation from data input, and after the program provided risk levels for the pathological changes in the mammary glands. The diagnosis of each patient being examined hadn't been revealed before the completion of electrical impedance mammography examination. The comprehensive clinical and instrumental examination was carried out for 42 patients with mastopathy or benign tumours of various degrees of severity and women with no pathological changes, as well as for 75 patients who had anatomically confirmed BC diagnosis (stages I-IIIC).

Methods:

The comprehensive examination of mammary glands (including electrical impedance computer mammography) was carried out for all patients. In this respect electrical impedance computer mammograph "MEIK" with software version 5.6 (manufactured by "SIM-Technika" ("Modern Impedance Medical Equipment")) was used.

The examination was carried out with the patient lying on her back on a couch. The examination commenced with the left breast. The mammary gland was moistened, levelled frontally to achieve optimal homogeneous geometry with the centre of the geometric symmetry in the nipple. If necessary, the patient's arm nearest to the breast under examination was raised, her hand placed behind her head. The remote electrode, presented by two ECG-electrodes, was attached to the forearm of the opposite arm of the patient. Upon moistening of the mammary gland, the panel with electrodes (256 electrodes, circumference 12 cm) was placed against the breast in such a way that the laser marker was positioned on the nipple, the position of the device being changed until achieving maximum contact area and exclusion of poor contacts. If the mammary gland wasn't completely covered by the panel, the examination was carried out by segments, clockwise (upper-outer-lower-inner segment). During the examination the device injected weak alternating electric current (50 kHz) into the patient's body and measured the distribution of the electric potentials on the surface of the body. The data acquired during this procedure was used for the reconstruction of the electrical impedance image, realized on the screen of a laptop computer connected to the device via USB port. When the reconstruction was finished, seven consecutive scan planes, which correspond to sections of the mammary gland in axial (base) view with the depth increasing from 0.4 to 5.2, i.e. from the areolar area to the retromammary space, were analysed.

When analysing the data of the MEIK-examination the conclusions were drawn on the basis of evaluation of graphical, numerical and visual characteristics. Each parameter had its own informativity point. Therefore their sum indicated the degree of threat coming from the existing lesions as well as the risk of their development, even if X-ray and ultrasound examinations didn't reveal any pathological changes.

Graphical Evaluation

The electrical conductivity distribution graph characterizes the frequency of occurrence of different tissues within a range of interest. It's a statistical value. The evaluation of the diagram of electrical conductivity in breast tissues is presented by the Gaussian distribution, but it is shifted to the left.

The electrical conductivity distribution graph provides information on the uniformity of tissue within a scan plane at a corresponding depth. In case of the absence of abnormal structures in the breast tissue, the distribution graph is unimodal; it is located on the left side of the coordinate system and has flatter descending segment of the curve.

In case of the inclusion of additional fibrous or adipose tissues, the graph acquires additional peaks (extremums), which are located to the left of the base peak. In case of the inclusion of additional tissues, consisting of liquid structures (cysts) or represented by cells with large transmembrane potential (proliferating cells, elements of inflammation), there are additional extremums located to the right of the base peak of the graph. If the tissues of abnormal conductivity are recompensed by the surrounding healthy tissue, the graph can be unimodal, but the ascending segment of the curve flattens. In addition to these types of electrical conductivity distribution, there are graphs without the ascending segment of the curve. The abovementioned type of electrical conductivity distribution occurs in case of low statistics for electrical conductivity: small size of a gland or a significant reduction of metabolic activity within breast tissues: typical condition after chemotherapy or therapy aimed at decrease of metabolic activity. In the latter case, the electrical conductivity graphs for the affected gland are located sharply to the left or do not possess ascending segments of the curve in contrast to the healthy gland. Therefore, the divergence between the electrical conductivity distribution graphs of the two mammary glands of the same woman is an additional and a very important parameter characterizing the presence of pathological changes in the breast. The divergence of electrical conductivity exceeding 15% is considered pathological.

Numerical Characteristics

We analysed the numerical parameters which described the electrical conductivity of the mammary gland: mean, maximum, extremum, minimum. The numerical characteristics quantitatively describe the electrical conductivity distribution diagram. Normal average conductivity value is 0.36 ± 0.12 . The normal average values may increase with age, but still cannot exceed 0.48 ± 0.11 . In order to make a conclusion about the normal or abnormal excess of mean values for a woman of a specific age group, the mean values should be assessed relatively to the extremum. Extremum is the most common conductivity in the tissues of the breast under analysis.

In the case of an ideal Gaussian distribution, mean values correspond to the most frequent event. Mean values and extremums are always equal. In case of mammary gland examination, values of the extremum, which are lower or equal to the mean ones, are considered as normal. When the relation of extremum to mean values exceeds 1, this fact is considered as an additional parameter indicating the presence of pathological changes in the mammary gland.

The maximum and minimum values characterize electrical conductivity in the region with the minimum and maximum impedance, respectively. MEIK 5.6 software measures the conductivity in the breast tissues in siemens, neutralizes noise and converts the values of the conductivity in conventional units, calibrating them in the range from 0 to 1. The assigned value to statistically significant amount of tissue with minimum conductivity is 0; the assigned value to statistically significant amount of tissue with maximum conductivity is 1. If the results meet values less than 0 or greater than 1, it indicates that the device has recorded statistically insignificant accumulation of tissue with abnormally low or high electrical conductivity or that the examination procedure hasn't been carried out correctly (too many poor contacts) – the facts that should be considered when analysing the results. In case of proper examination procedure maximum values of electrical conductivity should not exceed 1 and may be represented only by the lactiferous sinus zone. An important parameter characterizing the risk of pathological changes is the sharp drop of electrical conductivity within one area. Therefore, the relation of maximum value to mean values of electrical conductivity is estimated as a parameter to assess pathological changes of a breast. Three-fold excess of the maximum values over the average indicates that there is an additional indication of changes in the mammary gland.

Visual Evaluation

Normally, the visual image of the functional status of the mammary gland coincides with its structural organization. On the scan planes which are close to the skin surface, the area of heightened electrical conductivity should be visualized at the centre. It characterizes the lactiferous sinus zone, which (starting at 3 cm depth) abruptly transitions in the section of the same shape with a sharp decrease of conductivity; the circle of heightened electrical conductivity (0.7 ± 0.09), which characterizes the glandular contour, should be visualized at a distance of 3-5 cm from the nipple (depending on the size of the breast). Other tissues should be of mosaic state without drops of conductivity. Absence and / or disturbance of the nipple structure and / or glandular circle provide additional points in the evaluation of the criteria that characterize the pathological changes in the mammary gland.

Abnormal Areas

In case of visual detection of additional abnormal areas, disturbing the structure of the breast, an independent analysis with the help of the abovementioned numerical parameters is required. High gradient of electric potential at the border of high and low impedance in the local area is an important criterion for assessing the risk of BC development. Three-fold excess of the maximum values of electrical conductivity over the minimum values in a local area of anomalous conductivity is considered as an additional criterion, indicating the pathological changes. Graphical evaluation of homogeneity of electric

potential distribution is not applicable for the local area, due to non-uniform tissues surrounding the anomalous area. Calibration diagrams are used for graphical evaluation of the functional homogeneity of the medium. The change in the mean values of electrical conductivity at different scan depths is estimated. Normally, the mean values of electrical conductivity decrease with the increase of depth. The analysis of the mean values of the local area is inappropriate because of low statistics and inability to distinguish the analysed area on all scan planes reliably enough. The areas with heightened electrical conductivity are of special interest. Therefore, the graphs of the electrical conductivity variation are plotted mainly from the areas of low impedance so that maximum values are analysed. For convenience in the calculation, the deviation of the true curve of electrical conductivity decrease in the analysed region is assessed to its own exponential trend lines.

On the basis of all the above mentioned criteria, there was developed a program for mathematical treatment of all the criteria which was able to assess the probability of pathological changes in the breast. If all the criteria indicate pathological changes, the probability should amount to 100%.

In terms of comprehensive examination of mammary glands all the patients underwent ultrasound and digital X-ray mammography examination on equipment designed for comprehensive breast examination (with due account for patients' age).

The ultrasound examination showed that 65.8% (77) women suffered from nodules in the mammary gland (100% match with the results of digital X-ray mammography examination), 64% (75) of them with the anatomically confirmed BC and 1.7% (2) with benign tumours (1 - fibrous adenoma, 1 - fibrolipoma). In 13.7% (16) of cases physiological involute processes in the mammary glands were detected (fibro-fatty, fatty involution) (81.25% match with digital X-ray mammography), in 10.3% (12) - diffuse fibrocystic mastopathy (33.3% match with digital X-ray mammography), in 8.5% (10) - diffuse fibrous mastopathy (60% match with digital X-ray mammography), in 3.4% (4) - single cysts (50% match with digital X-ray mammography) among the patients with physiological involute changes and mastopathy. Normal condition of mammary glands was detected in 5.1% (6) of cases (66.7% match with digital X-ray mammography). The digital X-ray mammography examination showed that 65.8% women suffered from nodules in the mammary gland (100% match with the results of US examination), 1.7% (2) – from mammary gland fibroma (US examination showed fibro-fatty and fatty involution, 0% matches), 12.8% (15) — physiological involute processes (100% match with US), 6.8% (8) — diffuse fibrocystic mastopathy (62.5% match with US), 3.4% (4) — diffuse fibrous mastopathy (100% match with US), 1.7% (2) single cysts among the patients with physiological involute changes (100% match with US), 0.85% (1) — diffuse fibrocystic mastopathy with scattered micro calcifications. Normal condition of mammary glands according to the digital X-ray mammography examination was detected in 5.1% (6) of cases (66.7% match with the US).

Electrical impedance computer mammogram examination showed abnormal distribution of electrical conductivity with varying risk levels in 98% of pathological cases detected by standard breast examination procedures. The higher was risk level, the higher were the indications for medical and surgical treatment. If there were indications for medical treatment according to standard clinical and instrumental examination, the possibility for pathology development determined by electrical impedance computer mammogram examination amounted to 54.25% +/-12.4. If surgical treatment was required, the possibility for pathology development determined by electrical impedance computer mammogram examination amounted to 57.75% +/-11.2. The possibilities for the development of changes in case of various pathologies of the mammary gland are shown in Table 1.

Table 1

Pathology of the mammary gland	Norm	Cancer	Diffuse fibrocystic mastopathy	Diffuse fibrous mastopathy	Fatty involution	Fibro-fatty involution	Benign tumour
Average values of pathology possibility after electrical impedance computer mammogram examination,%	30.5	59.5	42	44.5	53.75	42.125	52.5
Deviation from mean, %	10.89636	11.96244	12.25328	14.48809	4.924429	18.96237	0.707107

For risk assessment and recommendations a special program designed for electrical impedance computer mammogram examination was used. It takes into account the following factors: the amount of extremums (can be found in the graph below the electrical conductivity distribution image), the occurrence of the factor, when the second extremum is higher than the first, mean and maximum values of electrical conductivity, extremum excess over the values, exceedance of the maximum values over the mean values, visualization of the nipple, nipple disturbance, visualization of glandular contour, the disturbance of glandular contour structure, the occurrence of abnormal electrical conductivity, the occurrence of the contour around the region with abnormal electrical conductivity, maximum and minimum electrical conductivity in the focus, electrical current gradient, maximum value deep in the focus. In case of occurrence of any of the indications for the risk assessment a certain points are allocated, which then are used to calculate the total score indicating the risk level.

When analysing the data acquired by means of electrical impedance mammography the conclusion is based on the assessment of graphical, numerical, and visual characteristics. Electrical conductivity distribution graph provides information on the uniformity of tissue within a scan plane at a corresponding depth. In case of the absence of abnormal structures in the breast tissue, the distribution graph is unimodal; it is located on the right side of the coordinate system and has flatter descending segment of the curve. This being said, the mean conductivity values on a par are 0.48 and extremums — 0.36. In case of abnormal inclusions occurrence the graph changes. In case of the inclusion of additional fibrous or adipose tissues, it acquires additional peaks (extremums), which are located to the left of the base peak.

The parameter characterizing high risk of disease development is a sharp drop of electrical conductivity within a gland. Three-fold excess of the maximum values over the mean values of electrical conductivity is considered as a pathological criterion.

When carrying out visual assessment, special attention is paid to the electrical impedance image where sharp visualization of the nipple and glandular contour must be preserved. Normally, a nipple has maximum electrical conductivity and is visualized as a sharp circular mono-impedance flat area less than 1 cm in diameter. Heightened electrical conductivity in the lactiferous sinus zone is reflected in 3-4 scan planes, and in the following scan planes it abruptly changes to a hyper impedance spot of the same diameter. This fact is an additional criterion of a pathological condition.

The glandular contour is characterized by heightened electrical conductivity (0.6-0.8), which does not exceed electrical conductivity in the nipple area. Normally, these areas circumscribe a virtual circle. Pathological condition of the breast can be characterized by the absence or disturbance of the structure of a glandular contour virtual circle.

In this research, the areas with anomalous electrical conductivity were studied separately. Besides the fact of the occurrence of these areas, the presence of the areas with sharply opposed conductivity (the presence of the contour) around them was assessed too. Two areas of markedly different electrical conductivity located closely can lead to a current gradient, which increases the risk of changes in this area, even if there is no lesion yet. Therefore, the relation of maximum conductivity to minimum conductivity in the area of abnormal electrical impedance was assessed too. Three-fold excess of the maximum values of electrical conductivity over the minimum values was considered as a risk factor for the development of pathological changes.

The behaviour of electrical conductivity depending on the depth of the measurement was assessed too. In the case of occurrence of abnormal conductivity areas, such areas were also analysed. In the absence of such an area, the graph was plotted for the mean values of the entire gland. Normally, it should have an exponential form. Non-exponential form indicates a pathological condition.

To each of these criteria a point for the risk of pathology is assigned. The relation between the sum of these points and the maximum possible sum multiplied by 100 determines the risk of pathology development, expressed in per cents for each gland. Keeping in mind high sensitivity of electrical impedance techniques and in order to take into account individual peculiarities of patients' organisms, an additional criterion was introduced: the relation between the risks in both mammary glands. If for one of the glands the risk of pathological changes was greater than average risk for both glands (more than 10% difference) this fact was considered as the indication of the extremely high risk of pathology.

For convenience of evaluation, there was developed a program for automatic (computer-assisted) diagnostic in Microsoft Excel format. The program allows an operator to answer questions concerning the acquired image in a test-like mode and as a result to obtain data about the possibility of pathological changes and the risk of disease.

According to the results of clinical trials "electrical impedance computer mammograph" detected the third level risk of disease development in 96% (72 patients) of cases and the second level of risk in 4% (3) of cases (this level recommendations include an additional examination (follow-up)) out of 75 patients who had been diagnosed with cancer. False positive results were found in 12.61% of cases. It indicates that this group of patients requires close follow-up. Thus, the effectiveness of the method amounted to 87.39%.

Conclusion

On the basis of the complex examination of mammary glands the effectiveness of the method of electrical impedance computer mammography amounted to 87.39%. Taking into consideration that the method is radiation-free, it can be recommended to use in outpatient clinics, antenatal clinics and maternity hospitals.

The method of electrical impedance computer mammography can be implemented as a screening method for the detection of pathological changes in the mammary glands on patient's first visit and for medical treatment monitoring. Detection of abnormal changes in the electrical impedance computer mammograms requires compulsory follow-up: clinical examination, ultrasound and X-ray mammography.

The method of electrical impedance computer mammography provides a safe, comfortable, fast and informative examination.

Head of Diagnostic Department,

PhD, Professor Sedykh S.A.

Head of Department of General Oncology,

PhD, Professor Pak D.D.

Investigator, JRF, Department of General Oncology,

Cand. Sci. (Med.) Ermoschenkova M.V.